

Triple-C SMAS Plication Facelift for Natural Facial Rejuvenation

Kevin Sadati, DO*
Saba Motakef, MD†

Background: Various methods are used to reposition the superficial musculoaponeurotic system (SMAS) during facelift procedures. This study presents a novel, radially oriented, layered SMAS plication: the triple-C SMAS plication. This technique utilizes customizable vectors in the pattern of a “C” to plicate the SMAS in 3 layers to lift and tighten the deep structures of the face.

Methods: A retrospective review was performed of patients undergoing the triple-C SMAS plication over a 1-year period. Patients with a length of follow-up less than 100 days were excluded from the study. Demographic data, operative data, complication rates, and satisfaction rates were assessed.

Results: One hundred ninety-one consecutive patients underwent a triple-C SMAS plication over a 12-month period. One hundred ten patients met inclusion criteria. Average follow-up was 404.5 days. Complications assessed included temporary facial nerve neuropraxia (0.91%), major hematoma (1.82%), minor hematoma (2.73%), seroma (4.54%), great auricular nerve injury (0%), postauricular skin slough >2 cm (1.82%), and infection (0.91%). Two revision procedures were performed (1.82%). Patient satisfaction rate was 96.4%.

Conclusions: Traditional SMAS plication techniques involve single-layer, straight-line plications to lift the lower face and neck, limiting their versatility. The triple-C SMAS plication represents a novel technique to safely and effectively elevate the deep structures of the face in a radial pattern to restore a more youthful contour to the malar area, jawline, and neck. This represents a unique strategy for face lifting by which excellent results can be consistently obtained. (*Plast Reconstr Surg Glob Open* 2019;7:e2575; doi: [10.1097/GOX.0000000000002575](https://doi.org/10.1097/GOX.0000000000002575); Published online 26 December 2019.)

INTRODUCTION

Facelift surgery represents the most powerful procedure in the plastic surgeon’s armamentarium to address the stigmata of aging of the face and neck. Since the technique was first described at the turn of the 20th century, facelift surgery has undergone a series of critical refinements as our knowledge of facial anatomy and aging processes has advanced. Initial descriptions of the technique involved elliptical skin excisions to tighten the skin and soft tissues of the face.^{1–3} However, these methods were significantly limited in their scope and efficacy.

Later descriptions would employ various degrees of skin undermining and excision.^{4,5} Although these methods could tighten the skin envelope more effectively, they did not address the superficial musculoaponeurotic system (SMAS) and the deeper fat compartments of the face, thus lacking in longevity and reliability.

The last 50 years saw tremendous advances in our knowledge of facial anatomy, and with them, the foundations of contemporary facelift surgery. Skoog⁶ described the first deep-plane technique in 1974. Recognizing the strength and durability of the deeper structures of the face, Skoog⁶ elevated and advanced the skin, superficial fascia, and platysma as a single, composite unit. In 1976, expanding Gray’s concept of the *fascia superficialis*,⁷ Mitz and Peyronie⁸ defined the anatomy of the SMAS as a superficial fascial system that invested the facial mimetic musculature and was continuous with the platysma, temporoparietal fascia, and galea.

From *Private Practice, Newport Beach, California; and †Department of Plastic Surgery, Loma Linda University, Loma Linda, California.

Received for publication July 21, 2019; accepted October 18, 2019.

Clinical question/level of evidence: Therapeutic, III.

Copyright © 2019 The Authors. Published by Wolters Kluwer Health, Inc. on behalf of The American Society of Plastic Surgeons. This is an open-access article distributed under the terms of the [Creative Commons Attribution-Non Commercial-No Derivatives License 4.0 \(CCBY-NC-ND\)](https://creativecommons.org/licenses/by-nc-nd/4.0/), where it is permissible to download and share the work provided it is properly cited. The work cannot be changed in any way or used commercially without permission from the journal.

DOI: [10.1097/GOX.0000000000002575](https://doi.org/10.1097/GOX.0000000000002575)

Disclosure: The authors have no financial interest to declare in relation to the content of this article.

Related Digital Media are available in the full-text version of the article on www.PRSGlobalOpen.com.

Further advances in our understanding of facial anatomy bolstered the foundations of modern facelift techniques. In 1989, Furnas⁹ established the concept of the retaining ligaments of the face—consistent, fibrous condensations that tether the skin to deeper facial structures. In 2006, Rohrich and Pessa¹⁰ demonstrated that facial fat is organized into distinct, anatomic subdivisions. According to these authors, the retaining ligaments of the face can be identified at the borders of these compartments.

Our current understanding of the processes of facial aging has been critical in shaping current practices. We now know that aging is far more complex than a purely gravitational process. Ultimately, aging leads to descent, atrophy, and radial expansion of superficial and deep facial structures.¹¹ The fundamental goals of facelift surgery are therefore to harmoniously elevate the structures of the face to highlight the natural contours that define the malar area, jawline, and neck.

The ideal facelift procedure achieves these objectives safely and efficiently in a simple and reproducible fashion, while minimizing downtime. With these goals in mind, we present our technique for natural facial rejuvenation—the triple-C SMAS plication. This unique strategy employs a layered, radially oriented SMAS plication utilizing permanent and absorbable sutures to reliably lift and tighten the superficial and deep structures of the face.

METHODS

Surgical Technique

With the patient in the upright position, incisions, the extent of skin flap dissection, and platysmal bands are marked. All procedures are performed in our outpatient operating facility with local anesthesia and sedation (10 mg Diazepam orally, 1–2 mg Midazolam intravenously). Dilute local anesthetic solution is prepared with 15 cubic centimeters (CCs) 2% lidocaine with 1:200,000 epinephrine, 15 CCs 0.25% bupivacaine with 1:200,000 epinephrine, 10 CCs 8.3% sodium bicarbonate, 0.1 CC 1:1,000 epinephrine, and 50 CCs normal saline. This solution is infiltrated throughout the area of the planned dissection using a 27-gauge needle. Approximately 70 CCs are administered over each side of the face and neck.

An incision is made just posterior to the submental crease. Dissection proceeds sharply under direct visualization to the level of the thyroid cartilage. Open liposuction is then performed with a 2.7 or 3.7 mm cannula to contour the neck. Care is taken to remain 1 to 2 finger breadths inferior to the body of the mandible to avoid excessively thinning the skin flap before vertical translocation (See [Video 1](#) [online], which demonstrates neck liposuction).

In patients with platysmal banding and anterior laxity, the platysma is horizontally transected a distance of 2–3 cm on either side, inferior to the hyoid. For patients with subplatysmal fat deposits, the platysma is minimally undermined and subplatysmal defatting is performed before midline platysma plication with 3-0 Vicryl sutures

(Ethicon Inc., Bridgewater, NJ). For patients with minimal anterior laxity and platysmal banding, the neck is primarily addressed laterally; however, open liposuction and contouring of the neck is performed in the majority of patients (See [Video 2](#) [online], which demonstrates the platysmaplasty procedure).

Dissection over the face begins with a temporal then posttragal incision that travels around the lobule and then posteriorly along the auriculomastoid groove with a back cut at the level of the root of the helix and then inferiorly along the retroauricular hairline ([Fig. 1](#)). In men, a pretragal incision is utilized. Incisions along the hairline are placed 1–2 mm posterior to the fine, vellus hairs. Incisions are made with a No. 15 blade, beveled across the hair shafts. Dissection begins retroauricularly with a No. 15 blade. Anteriorly, dissection over the parotid begins with a No. 15 then No. 10 blade under direct visualization to carefully define the skin-SMAS plane. Anterior to the parotid, dissection is performed with facelift scissors to the level of the lateral canthus ([Fig. 2](#)).

With skin flaps elevated, hemostasis is meticulously obtained. The triple-C SMAS plication is then designed. A radial, “C” shaped SMAS plication is designed approximately 3 cm anterior to the ear, extending from the root of the helix to the level of the lobule posteriorly ([Fig. 3](#)). This area will correspond to the subsequent SMAS plication. The degree of SMAS translocation and plication will depend on the laxity of the face and neck.

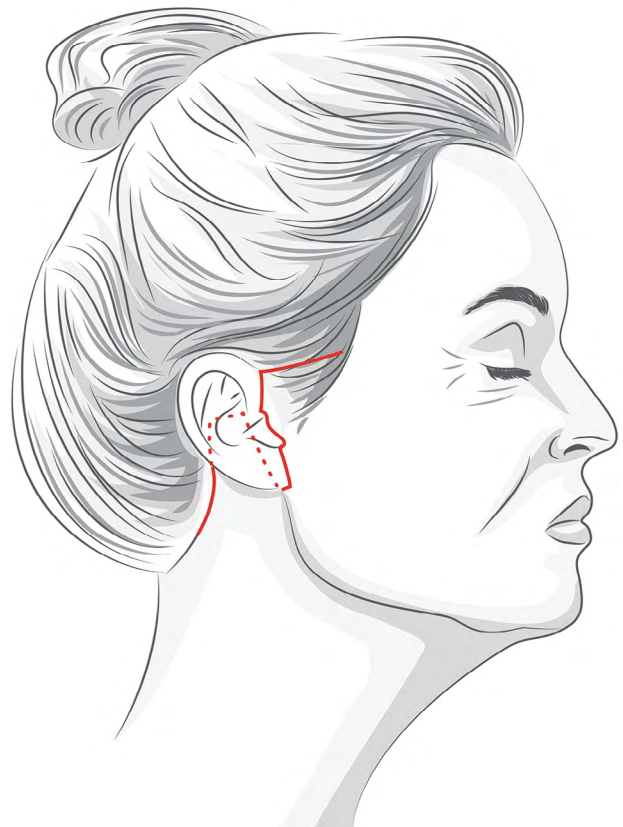


Fig. 1. Temporal and retrotragal incision design.

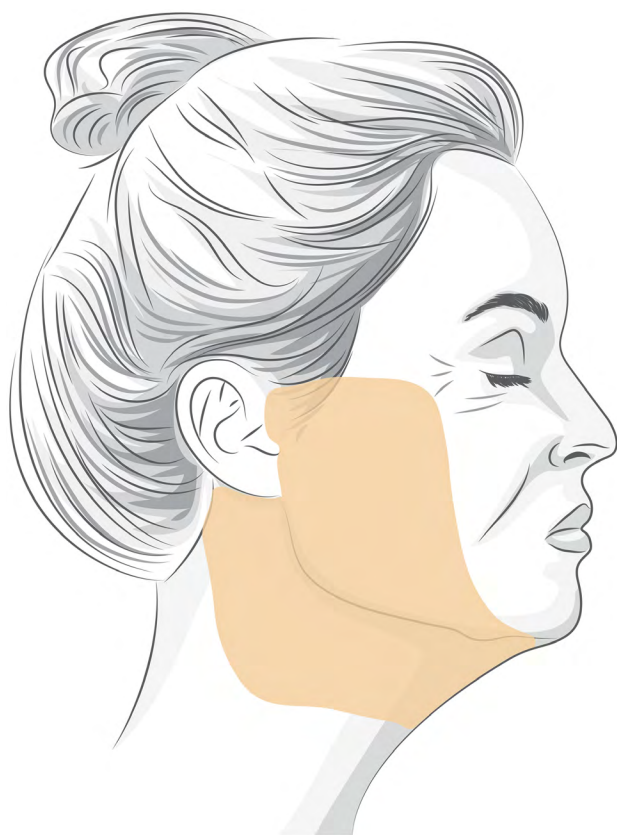

Fig. 2. Area of proposed skin flap undermining.

The triple-C SMAS plication is performed in 3 layers. The vector of the SMAS plication generally follows the 45-degree trajectory of the zygomaticus major, but vectors are modified based on patient needs. Each layer of the plication will address the neck, jawline, oral commissure, nasolabial fold, and midface. Differential vectors and tension can be applied to tailor the degree of SMAS tightening based on the degree of laxity in each corresponding area. The first layer of the triple-C SMAS plication (Fig. 4) is undertaken with 5-6 buried, interrupted 2-0 Mersilene sutures (Ethicon Inc.). This layer involves the most aggressive SMAS plication and will invariably lead to areas of bunching and irregularities of the SMAS and deeper soft tissues (Fig. 4). The second (Fig. 5) and third (Fig. 6) layers of the triple-C SMAS plication serve 2 purposes—(1) to bury the sutures of the first layer (the permanent Mersilene sutures will provide long-term durability and reliability but risk palpability and extrusion if placed superficially) and (2) to allow for smoothing, contouring, and refinement of the SMAS and deep soft tissues of the face. The second and third layers are performed with running, locking, horizontal mattress 2-0 Vicryl sutures (Ethicon Inc.). Suturing is continued until the soft tissues have been satisfactorily smoothed (See Video 3 [online], which demonstrates Part 1 of the SMAS plication; see Video 4 [online], which demonstrates Part 2 of the SMAS plication).

Skin is then redraped. The skin redraping and excision follows a primarily posterior trajectory over the face and a posterosuperior trajectory over the neck. Areas of

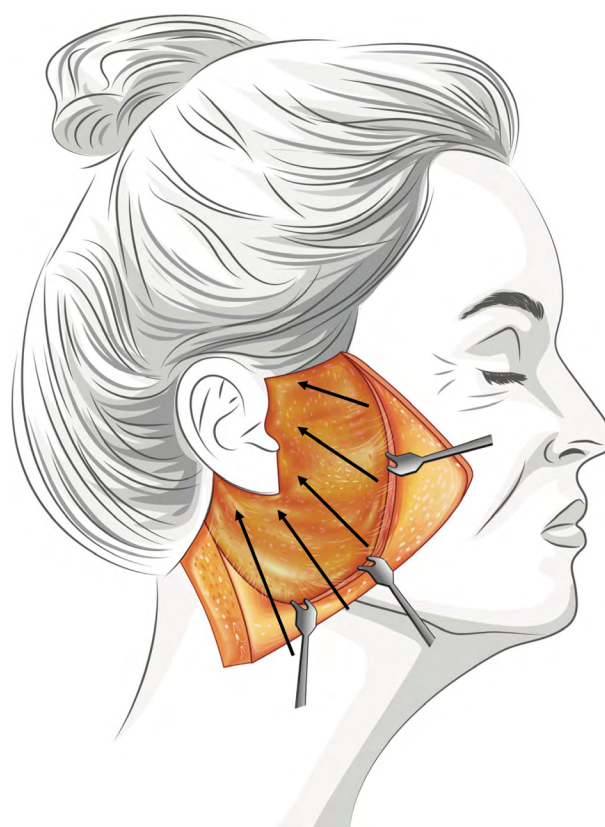


Fig. 3. Areas of proposed SMAS advancement for the first layer of plication and corresponding vectors are represented with black arrows. A minimum of 2–3 cm of tissue is routinely plicated in the first layer of plication. The second and third layers of plication will plicate an additional 0.5–1 cm of tissue. In the malar area and along the jawline, tissue is plicated anterior to the zygomatic osteocutaneous ligament and the masseteric cutaneous ligaments to recruit the mobile SMAS. Vectors are modified based on preoperative assessment and individual patient needs.

dimpling at the anterior margin of skin flap elevation are released with careful finger dissection at the skin-SMAS interface. Skin is then conservatively trimmed. The skin excision is beveled along the hairline to correspond to the initial incision. Minimal, if any, tension is placed over the skin closure following skin trimming and tailoring. The skin flap is inset with 4-0 Vicryl sutures anteriorly and posteriorly. The lobule is inset with a 3-point suture from skin flap, to lobule, to the underlying SMAS. A 10-French Jackson-Pratt (JP) drain is placed on either side in women. In men, 15-French JP drains are placed. Incisions are then closed with 5-0 Ethilon (Ethicon Inc.) sutures in a running, locking fashion. The incision over the neck is closed with 4-0 Vicryl sutures followed by running, locking 5-0 Ethilon sutures.

Epifoam (Biodermis, Inc., Henderson, NV) is placed to provide uniform compression over the face and neck, followed by a gauze roll and gentle compression with a Coban wrap (3M, Maplewood, MN). Patients are encouraged to ambulate frequently postoperatively and sleep with their head elevated. Patients are seen the following postoperative day (POD). Dressings and drains are



Fig. 4. First layer of SMAS plication, performed with interrupted, buried 2-0 Mersilene sutures. This represents the “load-bearing” layer of SMAS plication.

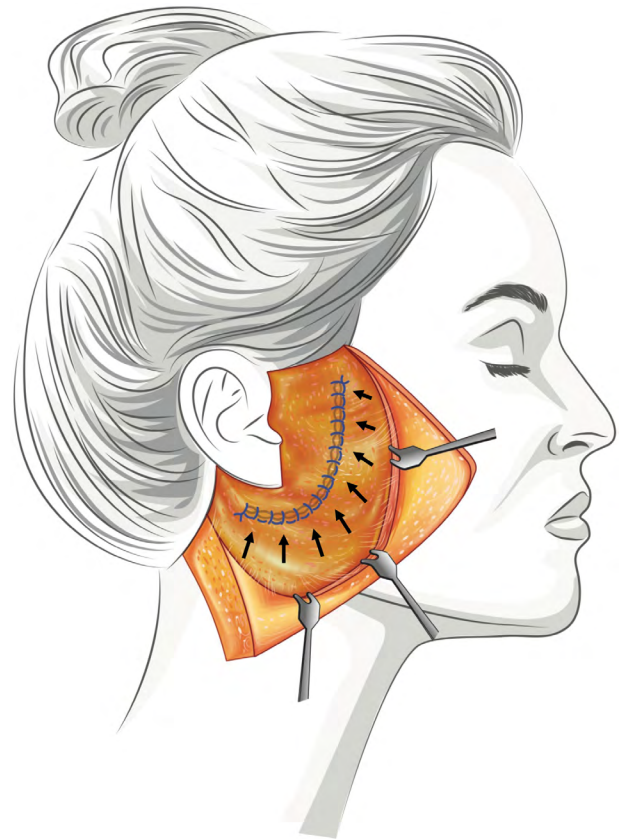

Fig. 5. Second layer of SMAS plication performed with 2-0 Vicryl sutures. This layer of running, locking sutures buries the underlying Mersilene sutures. Black arrows demonstrate corresponding vectors of SMAS plication.

removed. Patients are allowed to shower after POD 3. Patients are then seen on POD 7 for suture removal. The majority of patients are able to attend social functions within 1–2 weeks.

Data Collection

The authors performed a retrospective chart review of all patients who underwent triple-C SMAS plication facelift surgery performed by the senior author (K.S.) between January 9, 2017, and January 8, 2018. Data queried included demographic data, operative data, length of follow-up, complication rates, and patient satisfaction rates. Patients with a length of follow-up <100 days were excluded from the study. Patient satisfaction was assessed at patients' 8-week postoperative visit. Complications assessed included hematoma, seroma, postauricular skin slough >2 cm², facial nerve injury, great auricular nerve injury, hypertrophic scarring, and infection. Hematomas were categorized as major or minor hematomas. Major hematomas were those that required reoperation for treatment. Minor hematomas were hematomas <5 CCs that were treated with aspiration. Patients with any signs of erythematous or elevated scarring at 6 weeks postoperatively were categorized as having hypertrophic scarring and were treated with an injection of a mixture of triamcinolone 40 mg/mL and 5-fluorouracil. Repeat injections were administered at 6-week intervals as indicated. All procedures were in accordance with national

and international ethical guidelines for human research and the Helsinki Declaration of 1975.

RESULTS

One hundred ninety-one consecutive facelifts were performed over a 12-month period. One hundred ten patients followed up for at least 100 days and were included in this study. All procedures were performed in the senior author's outpatient operating facility in Newport Beach, California. Demographic data are summarized in [Table 1](#). One hundred seven patients were women and 3 were men. Average age was 65.0 years for men and 62.1 years for women. Average BMI was 23.6 kg/m² for women and 25.8 kg/m² for men. Average follow-up was 404.5 days.

The majority of patients underwent a primary facelift (81.8%). Secondary (14.5%) and tertiary (3.6%) facelifts were also performed. A total of 35 isolated facelifts were performed over the study duration. Average operative duration for isolated facelifts was 162.3 minutes. Sixty-five facelift procedures were performed with a total of 143 adjunct procedures. Average operative duration for combined procedures was 195.8 minutes. The most commonly performed adjunct procedures were laser skin resurfacing (35), upper blepharoplasty (33), lower blepharoplasty

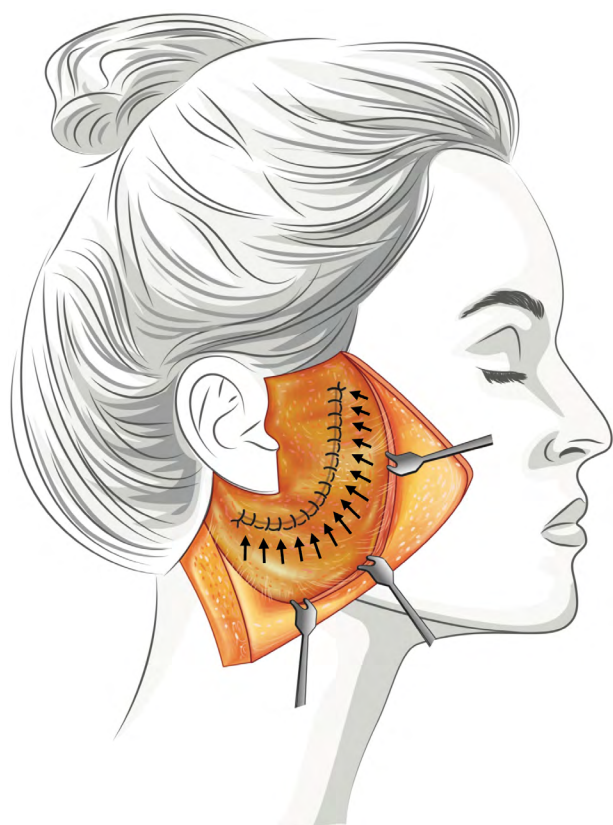


Fig. 6. Third layer of SMAS plication performed with 2-0 Vicryl sutures. This layer of running, locking sutures allows for additional contouring and refinement of the underlying SMAS. Vectors of radial plication are demonstrated with black arrows.

Table 1. Patient Demographics

	<i>n</i>
Men	3
Women	107
Nonsmoker	98
Former smoker	9
Smoker	3
	Mean
Age (men), y	65.0
Age (women), y	62.1
BMI (women), kg/m ²	23.6
BMI (men), kg/m ²	25.8
Follow-up, d	404.5

(15), neurotoxin injections (18), and fat transfer (10). Operative data are summarized in [Table 2](#).

Low morbidity was noted. Two major hematomas, 3 minor hematomas, and 5 seromas occurred in the study population. One patient was given a course of oral antibiotics for a mild infection. One neuropraxia involving the zygomatic branch of the facial nerve was noted in a patient undergoing a tertiary facelift. This resolved within 6 months with conservative management. No permanent nerve injuries occurred. Two patients developed postauricular epidermolysis in an area exceeding 2 cm². Twelve patients received steroid and 5-fluorouracil injections for hypertrophic scarring. Three patients developed Vicryl

Table 2. Operative Details

Operative time	
Mean all procedures, min	185.0
Mean isolated facelift, min	162.3
Mean facelift + adjunct procedures, min	195.8
Rhytidectomy	
Primary	90
Secondary	16
Tertiary	4
Adjunct procedures	
Fat transfer	10
Upper blepharoplasty	33
Lower blepharoplasty	15
Brow lift	5
Genioplasty	2
Laser	33
Hyaluronic acid filler	7
Neurotoxin	18
Buccal fat pad excision	5
Ear lobe reduction	6
Lesion excision	3
Chemical peel	1
Ear lobe reduction	4
Alar resection	1
Total	143

Table 3. Complications

Minor hematoma	2.73%
Major hematoma	1.82%
Seroma	4.54%
Mild infection	0.91%
Severe infection	0.00%
Hypertrophic scarring	10.91%
Neuropraxia (CN VII)	0.91%
GAN injury	0.00%
Skin slough >2 cm	1.82%
Dehiscence	2.73%
Prolonged edema	1.82%
Prolonged ecchymosis	0.00%
Contour irregularities	0.91%
Pixie ear	0.00%
Revision facelift	1.82%
Scar revision	3.63%
Suture extrusion	2.73%

CN, cranial nerve; GAN, great auricular nerve.

suture extrusion along the incision line; there were no instances of suture extrusion or palpability involving the sutures used for the SMAS plication. Two revision facelift procedures were performed during the study period. Overall patient satisfaction rate was 96.4%. Complications are summarized in [Table 3](#). Long-term, representative before and after photographs are shown in Figures 7 to 9.

DISCUSSION

In 2011, the senior author reported his experience with a double-C SMAS plication in 1,532 patients.¹² In the first 614 cases reviewed, the authors utilized a 2-0 Mersilene suture for both layers of the double-C SMAS plication. At this time, the Mersilene suture extrusion rate was 1.9% in women and 3.0% in men. Suture palpability, while not specifically addressed in this case series, was also noted to be an occasional concern. For the subsequent 918 cases in this series, 2-0 Vicryl was utilized for both layers of the SMAS plication, yielding a 0% extrusion rate. Although utilizing Vicryl suture effectively eliminated suture complications, upon reviewing our long-term outcomes, we have felt that Vicryl suture does not offer the long-term

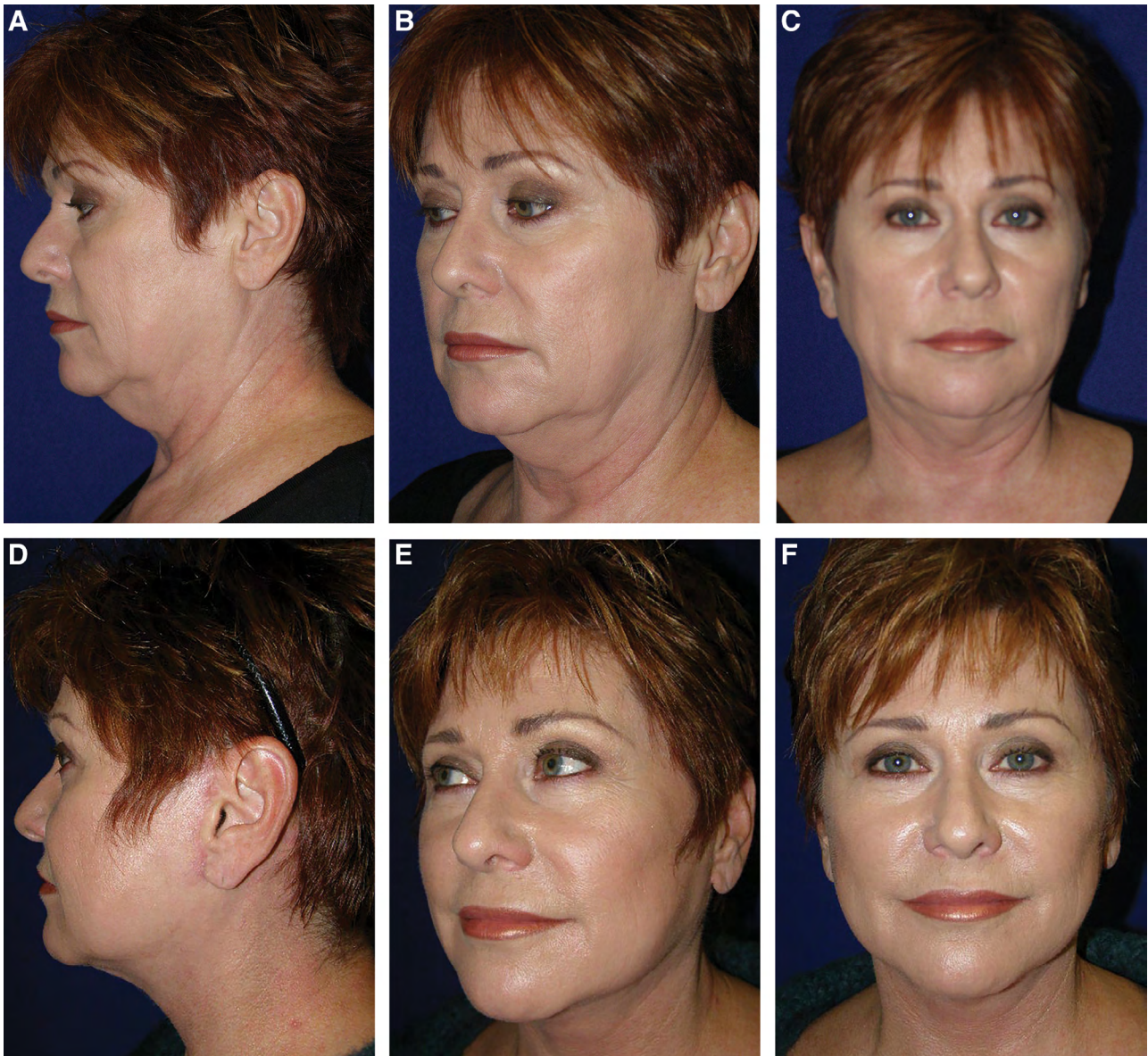

Fig. 7. Pre- and postoperative photographs of a 66-year-old woman who underwent an isolated rhytidectomy at age 54. Photographs are shown preoperatively (A–C) and at 2 months postoperatively (D–F).

reliability of a permanent suture. The triple-C SMAS plication utilizing 2-0 Mersilene for the deeper, load-bearing layer of plication followed by additional plications with 2-0 Vicryl sutures represents an important technical refinement. This technique offers a compromise between the reliability of a permanent Mersilene suture while minimizing suture complications by oversewing the load-bearing layer of the SMAS plication with absorbable Vicryl suture. In this study, although 3 patients developed Vicryl suture extrusion along their incision lines, no suture complications were noted for sutures used for the SMAS plication.

Our data demonstrate that the triple-C SMAS plication can be performed safely and efficiently. Over an average follow-up of 404.5 days, complication rates for this procedure were low. Only 3 major complications were noted in the study period, including 1 facial nerve neuropraxia and

2 major hematomas. The remainder of the complications noted in this study can be categorized as minor complications that resolved with conservative management.

The optimal facelift technique is one that is reliable, reproducible, efficient, and safe. To this end, numerous methods have been formulated that warrant discussion. It has been well established that skin-only techniques that do not utilize the SMAS to restore a youthful contour to the face and neck are inferior to techniques that employ some degree of SMAS modification because they lack reliability and place tension on the skin—a fundamentally elastic structure.¹³ Although composite skin-SMAS techniques offer more durability than skin-only techniques, the skin and SMAS must be moved as a single unit in the same direction. These techniques thus lack the versatility of a differential approach to skin and SMAS that addresses

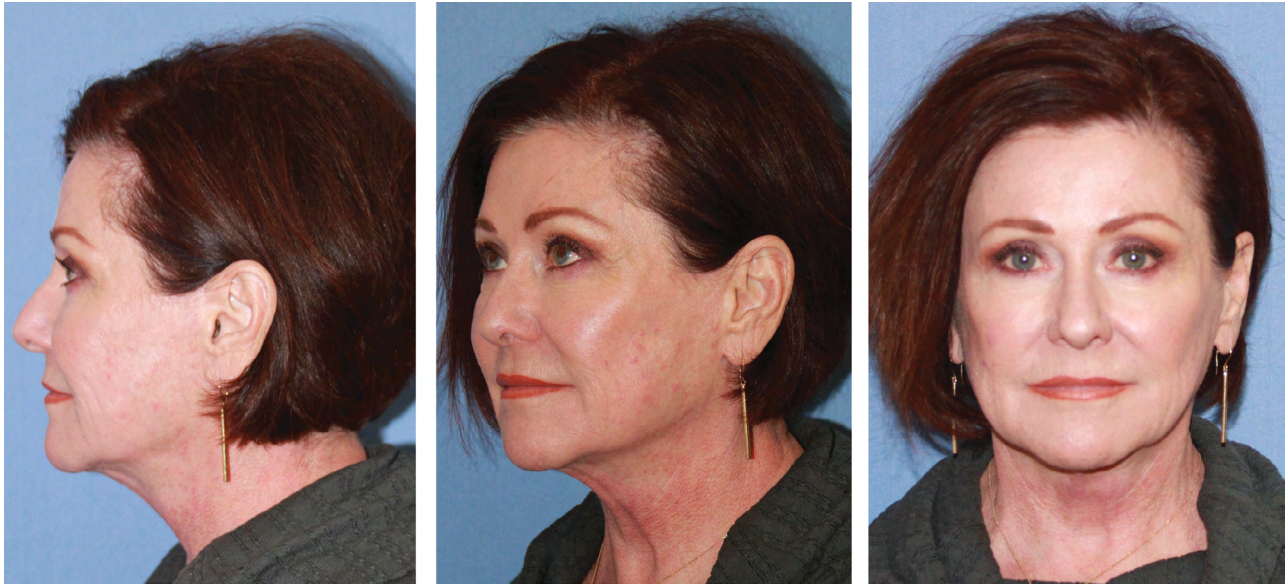

Fig. 8. The patient is shown 12 years postoperatively.

these structures separately.^{13,14} Various strategies within this realm have been discussed, including SMAS plication, SMASectomy, and dual-plane facelift techniques that elevate and translocate separate skin and SMAS flaps.

Although twin studies with long-term follow-up have shown that comparable esthetic outcomes can be achieved with each method,^{15,16} SMAS plication techniques provide tremendous advantages. Anteriorly based plication techniques elevate sagging fat to soften the nasolabial fold and restore a more youthful contour to the face.¹⁷ When properly planned and performed, SMAS plication procedures can be individually tailored to restructure and sculpt the soft tissues of the face.¹⁸ These techniques offer durability and longevity while avoiding a technically demanding and time-consuming sub-SMAS dissection. Because the SMAS will not be elevated, thicker subcutaneous flaps can be elevated, minimizing the risk of complications such as skin necrosis. Additionally, by avoiding SMAS elevation, the SMAS is not devascularized and potential atrophy of this layer is avoided. Theoretically, plication techniques place the facial nerve at lower risk by avoiding a sub-SMAS dissection. Rates of temporary facial nerve injuries have been estimated to be as high as 3.6% with deep-plane techniques.²⁰ Indeed, a recent meta-analysis reviewing data from 183 studies demonstrated a lower risk for facial nerve injury, skin necrosis, hematomas, and seromas for SMAS plication techniques.¹⁹

Traditionally, SMAS plication techniques have been described as single-layer, straight-line plications to tighten the face and neck. We feel that these methods lack a degree of versatility. The triple-C SMAS plication offers the flexibility of customizable vectors of plication to independently address laxity and descent of the face and neck with the first layer of the plication in the form of inverted, interrupted sutures. For example, to address significant laxity and descent of the midface, sutures are placed to resuspend the malar fat pad, adapting principles espoused by extended minimal access cranial suspension techniques.²¹ The running, locking, curvilinear trajectory

of the second and third layers of the triple-C SMAS plication is unique in comparison to traditional, straight-line plications in that it radially gathers, raises, and tightens the deeper structures of the face and neck. This approach better addresses age-related radial expansion of the face when compared with traditional plication techniques.

The double-layer, running, locking sutures offer other important advantages. An experimental study compared the strength of double-layer, running, locking sutures with horizontal mattress sutures in porcine skin specimens.²² Using a tensometer, the authors demonstrated that the running, locking method required more force to elicit plication failure. These findings suggest that this plication technique may yield more reliable tissue apposition.

It is noteworthy that the neck is routinely opened in the majority of our procedures. In addition to allowing for undermining and skin redraping, the open approach allows liposuction to be performed more safely and precisely.²³ In patients with significant anterior laxity and platysmal banding, the addition of a corset platysmoplasty allows for further refinement. As with the face, the approach to the neck is individualized according to each patient's needs and goals (Fig. 9).

Detractors of the SMAS plication technique argue that over time, sutures can tear or "cheese wire" through the SMAS, limiting longevity. However, it is conceivable that this problem could occur with any of the aforementioned techniques. Additionally, SMAS translocation can be limited by the retaining ligaments of the face, which can only be fully released via a sub-SMAS dissection. However, in the senior author's practice in Newport Beach, California, we have noted that modern facelift patients desire natural and durable facial rejuvenation with minimal down time. Although patients desire an effective and reliable operation, our patients want to soften and highlight the natural, youthful features of the face safely without dramatically altering the architecture of the face.

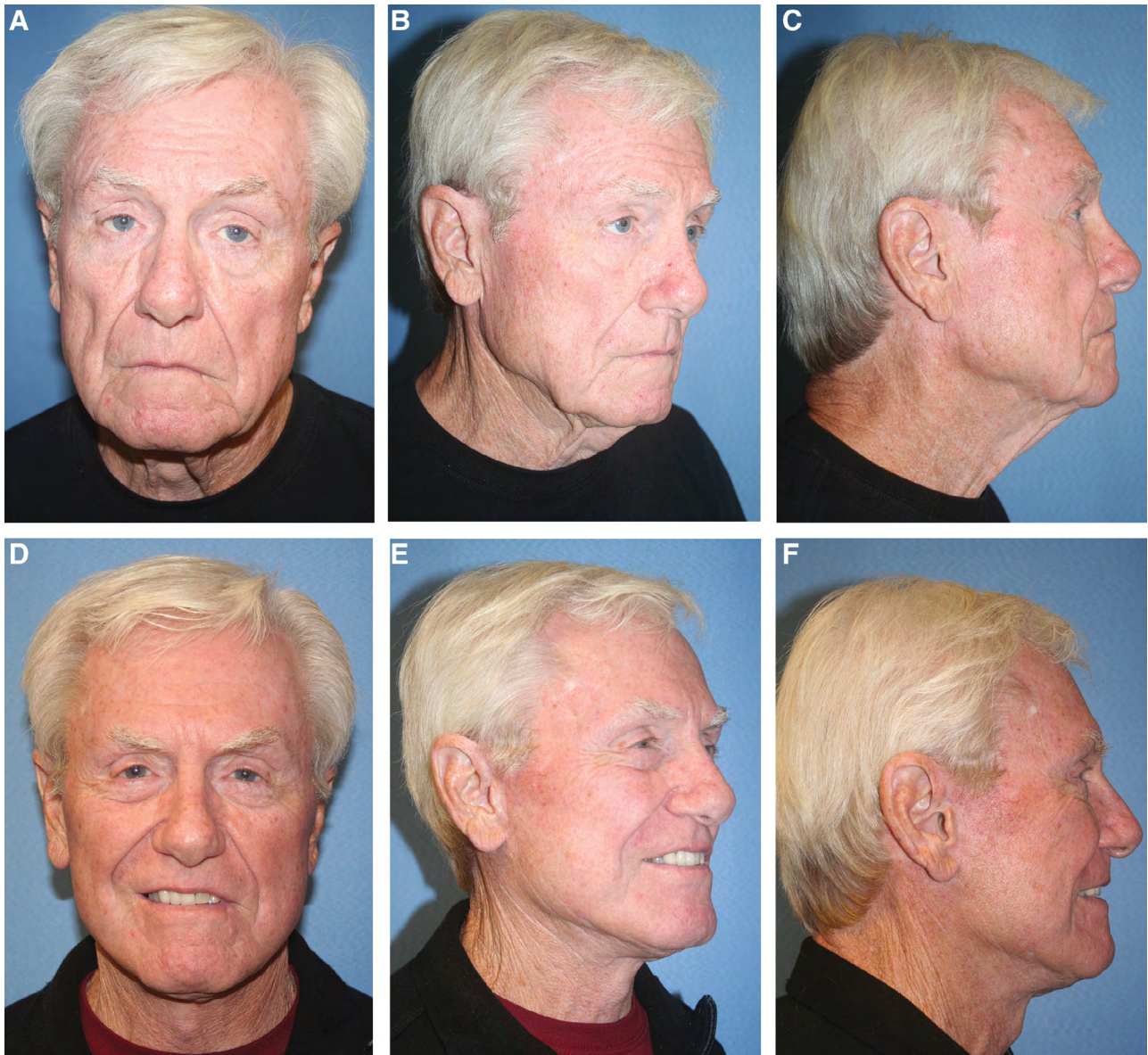


Fig. 9. Pre- and postoperative photographs of an 80-year-old man who underwent rhytidectomy with fat transfer to the face and laser skin resurfacing at age 79. Photographs are shown preoperatively (A–C) and 12 months postoperatively (D–F).

CONCLUSIONS

Since the inception of facelift procedures at the turn of the 20th century, various rhytidectomy techniques have been devised. Long-term data from a cohort of 110 patients demonstrate that the triple-C SMAS plication is a reliable, reproducible, efficient, and safe method for facial rejuvenation. This versatile technique allows for the creation of customizable vectors to lift and radially tighten the deep structures of the face based on preoperative analysis and individual patient needs. This method represents a unique strategy for face lifting by which excellent results can be consistently obtained.

Kevin Sadati, DO
 Gallery of Cosmetic Surgery
 359 San Miguel Dr #110
 Newport Beach, CA 92660
 E-mail: surgeon@drkevinsadati.com

ACKNOWLEDGMENT

The authors would like to thank Dr. Nicole Rouse, DO, for contributing the illustrations to this work.

REFERENCES

- Hollander E. Die kosmetische Chirurgie. In: Joseph M, ed. *Handbuch der Kosmetik*. Leipzig: Verlag von Veit; 1912:688.
- Lexer E. *Die Gesamte Wiederherstellungschirurgie*. Vol 2. Leipzig: JA Barth; 1931.
- Joseph J. Hangewangenplastik (Melomioplastik). *Dtsch Med Wochenschr*. 1921;47:287.
- Bames H. Truth and fallacies of face peeling and facelifting. *Plast Reconstr Surg*. 1927;126:86.
- Bettman AG. Plastic and cosmetic surgery of the face. *Northwest Med*. 1920;19:205.
- Skoog T. *Plastic Surgery – New Methods and Refinements*. Philadelphia: WB Saunders; 1974.

7. Gray H. *Anatomy of the Human Body*. 25th ed. Philadelphia: Lea & Febiger; 1949:352.
8. Mitz V, Peyronie M. The superficial musculo-aponeurotic system (SMAS) in the parotid and cheek area. *Plast Reconstr Surg*. 1976;58:80–88.
9. Furnas DW. The retaining ligaments of the cheek. *Plast Reconstr Surg*. 1989;83:11–16.
10. Rohrich RJ, Pessa JE. The fat compartments of the face: anatomy and clinical implications for cosmetic surgery. *Plast Reconstr Surg*. 2007;119:2219–2227; discussion 2228–31.
11. Stuzin JM. Restoring facial shape in face lifting: anatomic considerations and the role of skeletal support in facial analysis and midface soft tissue repositioning. In: Thaller SR, Bradley JP, Garri JJ, eds. *Craniofacial Surgery*. New York: Informa Healthcare; 2008:59–80.
12. Sadati K, Corrado AC. The double “C” plication technique: a reliable technique for lower facial rejuvenation: review of 1500 cases. *AJCS*. 2011;28:12–18.
13. Connell BF. Pushing the clock back 15 to 20 years with facial rejuvenation. *Clin Plast Surg*. 2008;35:553–566, vi.
14. Marten TJ. High SMAS facelift: combined single flap lifting of the jawline, cheek, and midface. *Clin Plast Surg*. 2008;35:569–603, vi.
15. Alpert BS, Baker DC, Hamra ST, et al. Identical twin face lifts with differing techniques: a 10-year follow-up. *Plast Reconstr Surg*. 2009;123:1025–1033; discussion 1034.
16. Antell DE, Orseck MJ. A comparison of face lift techniques in eight consecutive sets of identical twins. *Plast Reconstr Surg*. 2007;120:1667–1673.
17. Robbins LB, Brothers DB, Marshall DM. Anterior SMAS plication for the treatment of prominent nasomandibular folds and restoration of normal cheek contour. *Plast Reconstr Surg*. 1995;96:1279–1287; discussion 1288.
18. Little JW. Three-dimensional rejuvenation of the midface: volumetric resculpture by malar imbrication. *Plast Reconstr Surg*. 2000;105:267–285; discussion 286–9.
19. Tonnard P, Verpaele A, Monstrey S, et al. Minimal access cranial suspension lift: a modified S-lift. *Plast Reconstr Surg*. 2002;109:2074–2086.
20. Kridel R, W H, Soliemanzadeh P. The aging face (rhytidectomy). In: Bailey BJ, Johnson JT, Newlands SH, et al, eds. *Head & Neck Surgery – Otolaryngology*. Vol. 2. Philadelphia, PA: Lippincott Williams & Wilkins; 2006:2627–2650.
21. Jacono AA, Sean Alemi A, Russell JL. A meta-analysis of complication rates among different SMAS facelift techniques. *Aesthet Surg J*. 2019;39:927–942.
22. White JB, Barraja M, Mengesha T, et al. Avoiding early revision rhytidectomy: a biomechanical comparison of tissue plication suture techniques. *Laryngoscope*. 2008;118:2107–2110.
23. Feldman JJ. Neck lift my way: an update. *Plast Reconstr Surg*. 2014;134:1173–1183.